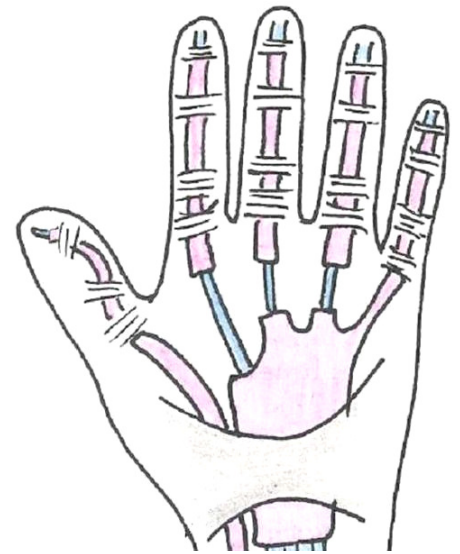


Best Practice Recommendations for Management of Flexor Tenosynovitis in the RA Hand

Description

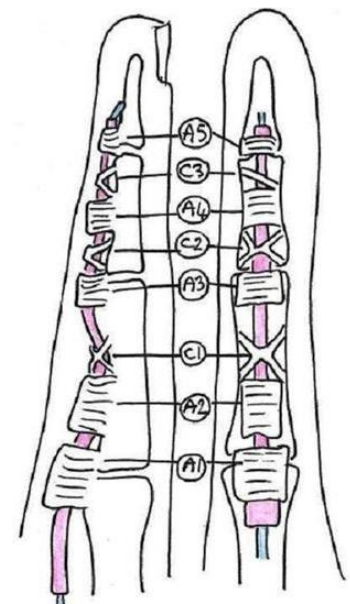
In Rheumatoid Arthritis (RA), flexor tenosynovitis is characterized by inflammation of the flexor tendon and the synovial lining of the tendon sheath. Each flexor tendon and its sheath run through a fibro-osseous tunnel (Fig.1) which can also become inflamed. These structures can thicken, resulting in a stenosing tenosynovitis. The mismatch between the size of the sheath, the tendon and the enclosing fibro-osseous tunnel means that the flexor tendon does not glide smoothly through the tunnel. Symptoms may include pain, swelling, crepitus, reduced speed or loss of movement, development of a nodule and possible tendon rupture (1,2,3).



© A. Fairleigh

Figure 1

Two different forms of tenosynovitis may occur; diffuse or nodular, or a combination of both. In the diffuse form, the inflammation is not localized and occurs along the full length of the tendon causing peritendinous effusion and hypervascularization of the sheath. This form is the most common in RA (1,3). In the nodular form, a thickening of the flexor tendon occurs in a localised area, most frequently at the sites of the A1 and A3 pulleys (Fig.2) (3). This results in a distinct, palpable nodule that causes locking of the finger, known as trigger finger. Most often symptoms arise at the A1 pulley site, at the level of the MCP joint, as it is subjected to the highest forces and pressure gradients during normal and power grip (4). Less frequently it occurs at the A3 pulley, at the PIP joint (5). The flexor tendons of the 2nd, 3rd and 4th fingers are the most frequently involved (6).



© A. Fairleigh

Figure 2

Pain may occur arising from the innervated tenosynovium. As the stenosis worsens, it becomes difficult to actively flex and extend the affected finger. The finger may lock in a flexed position, and it may need to be passively 'unlocked'.

Classification

The Amsterdam Severity Scale in Stenosing Tenosynovitis (ASSiST) (1)

Grade 0	No impairment
Grade 1	Palpable nodule or crepitation, with a normal active range of motion (AROM)
Grade 2	A perceptible click or a reduced tempo of active finger flexion with a full AROM (determined by the maximum passive range of motion)
Grade 3	Restriction in active range of motion by a tendon obstruction under the pulley or within the tendon sheath

Assessment

Pain

- Ask patient location of pain, typically at the A1 pulley, sometimes at A3 site (5).
- Ask patient if pain occurs at rest or activity.
- Ask patient to identify aggravating factors.
- Ask patient to indicate on a 10 point pain scale their level of pain in the past week.

Inflammation

- Observe for swelling along flexor tendon sheath in the palm and finger. In the diffuse form, swelling is typically along the length of the tendon. In nodular form, swelling is in the distal palmar area and over the proximal phalange.
- Palpate for swelling, tenderness or thickening along the flexor tendon sheath in the palm and the volar surface of the proximal phalange, with the hand in a relaxed position. Tenderness most commonly occurs at the site of the A1 pulley on the volar aspect of MCP joint.
- Palpate for a distinct nodule over the volar aspect of the MCP and PIP joints (1,7).

Finger Movement

- Active Movement: Ask the patient to fully flex and extend their fingers (8). Observe speed, smoothness and range of movement.
- Passive Movement: If active range is incomplete, passively flex and extend the fingers, including the MCP joints (8).
- Palpate each tendon separately in the distal palm (A1 site) and on the volar surface of proximal phalange (A3 site) during passive or active flexion and extension of fingers. Repeat finger motion several times if necessary to determine presence of crepitus or a nodule that may cause clicking or locking (1,7,9).

Special Test

Open & Close Hand 10 Times: Ask patient to open and close the hand 10 times. The number of triggering events (not locking) in 10 active full fists is scored out of 10. If patient's finger remains locked at any time in making 10 active full fists, the test is discontinued and an automatic score of 10/10 is recorded (9,10).

Differential Diagnosis: Other conditions include; Dupuytren's Contracture, flexor tendon or sheath tumours and MCP joint acute inflammation. Pain at the thumb MCP joint can be associated with De Quervain's tenosynovitis and sesamoid bone anomalies.

Treatment

The success of conservative management, reported in the literature, varies from 50-94% (5). Conservative management has a poorer outcome if multiple fingers are involved or if symptoms have persisted longer than 4-6 months; or if there is diffuse tendon thickening versus a discrete nodule or significant triggering (2,4).

Modalities:

Heat Therapy: Heat increases blood flow and extensibility of collagen tissues assisting in resolution of edema, decreasing joint stiffness and pain. Therapeutic heat modalities include hot pack, paraffin wax and hot water bath (10,11).

Suggested method (MPAP): 10 to 15 minutes each application, 2 to 3 times a day.

Low Level Laser Therapy: Laser light can penetrate the skin and activate the appropriate photoreceptor target. Once activated, the stimulated tissue can induce biological healing (12). Suggested method (13): Laser class 3B (789-860nm GaAlAs Laser), 8 Joules in total (2-3 points) .

Ultrasound (US) Therapy: US enhances blood flow, increases soft tissue extensibility, collagen synthesis, tissue repair and tensile strength of tendons (5,10,11,12).

Suggested method (MPAP): Under water or direct contact with US gel, 2 times a week for 3 weeks. Use pulsed US in acute stage. Use continuous US for thermal effect, to decrease pain.

Cryotherapy: Cryotherapy modalities include cold packs and ice cube massage. Ice massage may work best for the focal area of pain and inflammation. Advise patient about overuse and re-injury immediately following the application of cold because it may 'mask' pain until tissue temperature increases. Use caution with patients with Raynaud's phenomenon (5).

Suggested method (MPAP):10 minutes each application, 2 to 3 times a day, intensity and type according to patient's tolerance.

Contrast bath: Use for decreasing pain and swelling, increasing ROM.

Suggested Method (MPAP): Alternate hot (5 seconds) and cold (10 seconds), repeat for 10 minutes, 2 to 3 times a day, temperature according to patient's tolerance.

Massage:

Massage improves tendon function by increasing circulation and tendon nutrition, and by remodeling hypertrophic tendons, thus reducing tissue bulk at the pulleys (5,10,11,14,15).

Suggested Method (5,15): Evans and colleagues advocate massage of the entire tendon sheath and adjacent area. Cryriax popularized transverse friction massage, in which the clinician moves the patient's skin over the affected area perpendicular to tendon fiber orientation, with increasing pressure, working up to 15 minutes. If tendon and pulley are involved, the clinician should hold the tendon taut and mobilize perpendicular to the sheath. Teach patients to apply the technique themselves.

Exercise

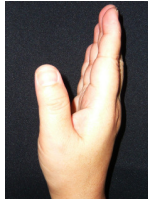For Diffuse Tenosynovitis:

Tendon gliding exercise: Use to help improve tendon nutrition and mobility.

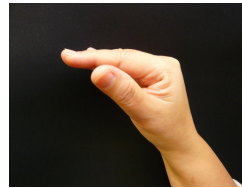
Suggested Method (MPAP): 5 repetitions using minimal effort, 3 times a day.

Starting Position (SP) → Table top → SP → Hook Fist → SP → Straight Fist → SP → Full Fist → SP

1. SP: Straight hand Position




2. Table Top: Keeping PIP & DIP joints straight, flex MCP joints. Return to SP. Use cautiously with intrinsic tightness.



3. Hook Fist: Keeping MCP joints straight, flex PIP & DIP joints. Return to SP.



4. Straight Fist: Keeping DIP joints straight, flex MCP & PIP joints. Return to SP.



5. Full Fist: Flex MCP, PIP, & DIP joints. Return to SP.

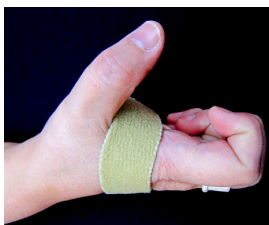

For nodular or triggering form:

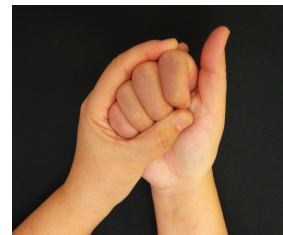Full and repetitive fisting should be avoided while symptoms persist (5).

Suggested method (MPAP) (16): 5 repetitions each exercise, 3 times a day.

1. Active hook fist in MCP blocking splint.



2. Passive full fist without splint.

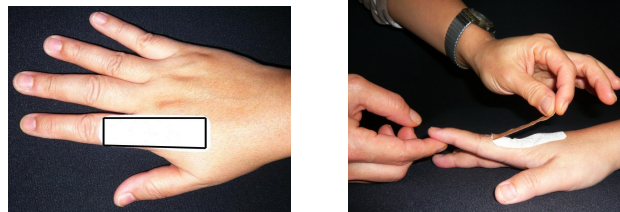


Taping:

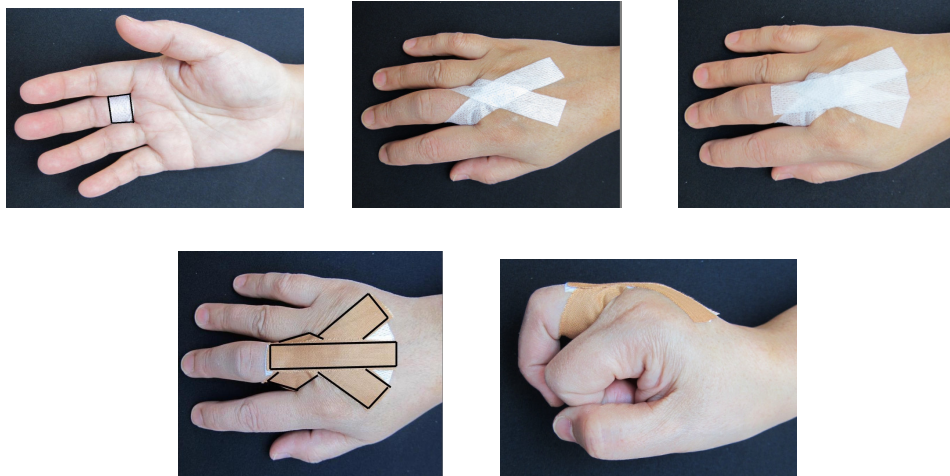
Taping reduces flexion at the MCP joint while allowing flexion at PIP & DIP joint.

Suggested Methods (MPAP): With the MCP joint in neutral position, apply cover roll without tension, then hyperextend MCP if possible, using Leukotape to restrict flexion of MCP joint,

Method 1: Attach the tape proximal to the dorsal surface of the PIP joint, then apply it to the dorsal aspect of the metacarpal.



Method 2: Attach the central part of the tape to palmar aspect of base of the proximal phalange. The two ends of the tape cross over to the dorsal aspect of MCP joint, attaching proximally to the dorsal aspect of the metacarpal. Apply a second tape as Method 1.



Physiotherapy Evidence:

Salim et al reported at 3 months, the success rate (absence of pain and triggering) for those receiving physiotherapy is 69%. The physiotherapy treatment group had no recurrence of pain or triggering, attributed to subjects' awareness of physiotherapy exercises and use of self management strategies (10,11).

Splinting

Purpose:

- To provide local rest for the flexor tendon and its sheath by limiting tendon excursion, in order to decrease inflammation, pain and associated triggering (5,16,17).
- To decrease mechanical friction of the flexor tendon at the A1 pulley by blocking MCP flexion during movement (4,14).
- To decrease mechanical friction of the flexor tendon at A3 pulley by blocking PIP flexion (4,14).
- To promote the use of a “hook fist” (MCP blocked, full PIP flexion) during exercise and ADLs, in order to encourage independent glide of FDS & FDP tendons which promotes synovial fluid circulation (14).

Guidelines:

- To guide choice of orthosis, hold the MCP joint in extension and instruct patient to actively flex the IP joint. Note the effect on pain and triggering (5). Repeat process, holding the PIP joint in extension and actively flex the MCP joint. This will help differentiate between A1 and A3 pulley site involvement.
- Assess the impact of splint on function and choose the least bulky and restrictive splint that accomplishes the goal (5,18).

Splint Options:

MCP Blocking Splints

Indications:

Pain and swelling due to diffuse tenosynovitis or triggering due to a nodule at the A1 pulley(14).

Description:

Splint holds MCP joint in 0-15° flexion and allows full PIP movement (2,5,9,14,18,19,20).

Literature suggests a higher compliance rate with splints that position MCP joint in 10-15° flexion versus 0°, because of improved hand function (9,18,20).

1. Palmar Ring (9,18,19,21)

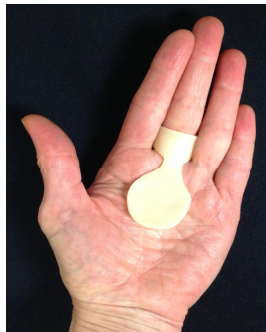- Splint optimizes hand function by allowing tip-to-tip prehension and full thenar motion (9).
- Custom fabricated from low temperature thermoplastic (2mm Taylor Splint or Redifit), for day and night use. Ring portion can open on dorsum to allow for PIP swelling or joint enlargement (9).
- A strap can be added to maintain contact of the splint to the palm to ensure correct MCP position.
- Metal MCP splint (Siris) used during the day only (5).

2. Dorsal Ring (MPAP)

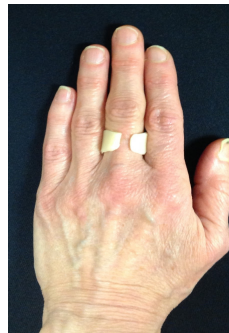- Splint optimizes hand function by leaving palm free for gripping.
- Strap required to maintain contact of the splint with the dorsum of the hand. Splint is padded over MCP joint dorsally to reduce pressure.
- For day use only.

3. Hand-based Palmar Splint (14,16, 20,22,23)

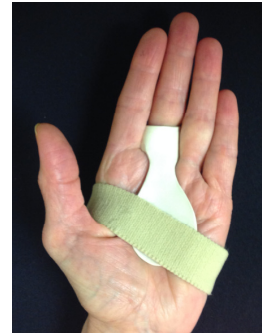- Useful when more than one finger is involved (16).
- Splint should allow full thumb opposition (20).
- Custom fabricated from low temperature thermoplastic (e.g. Taylor Splint, Polyform or Redifit), for day and night use.




Palmar ring



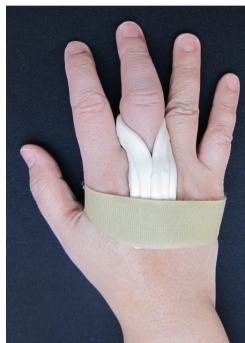Dorsal opening



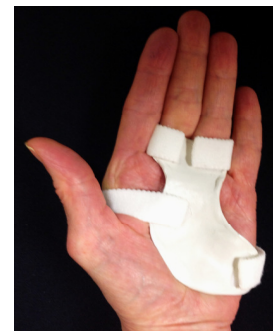With strap



Metal MCP



Dorsal ring



Hand based

Wearing Regime:

In the literature, there is a lack of consensus regarding duration of use, ranging from 3 - 12 weeks with 8-10 weeks most commonly used. Splints worn continuously or during waking hours only, until symptoms resolve (2,9,14,16,19,20,21,24).

Precautions:

- Ensure the thickness of the ring splint does not encourage ulnar drift in adjacent fingers.
- Splint may aggravate PIPJ inflammation.
- Splint may impair hand function if PIPJ flexion is limited.
- Daily ROM exercises are recommended to prevent joint stiffness (see page 4).
- Avoid tight fitting splints and check skin for pressure areas before wearing overnight.

PIP Joint / Thumb IP Blocking Splint

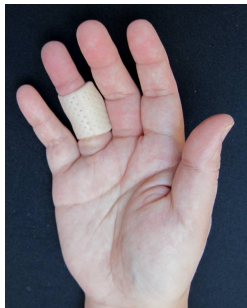Indications:

Pain, swelling or triggering, due to a nodule at A3 pulley in a single finger or at the A1 pulley in thumb (14,16). Also used with A1 pulley problems in the fingers when a less restrictive splint is required and with problematic locking on awakening (4).

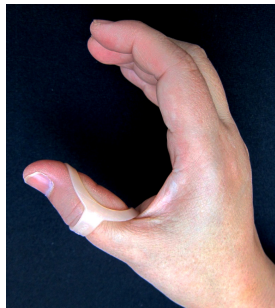Description:

Splint holds PIP joint in full extension, limiting flexor tendon excursion through the affected pulley. It allows free MCP and DIP joint range, optimizing hand function for gripping (16). For thumb IP splint, thumb pad is free for pinch and tactile discrimination (16).

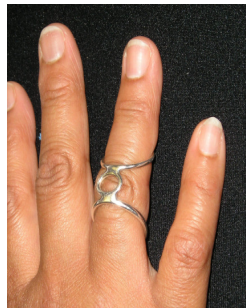1. Custom thermoplastic cylinder, for day and night use.
2. Reverse Oval 8 Swan Neck splint, for day use only.
3. Metal anti-boutonniere splint (Digisplint), for day use only.
4. PIP Volar Gutter, supports PIP joint in full available extension, for day and night use.



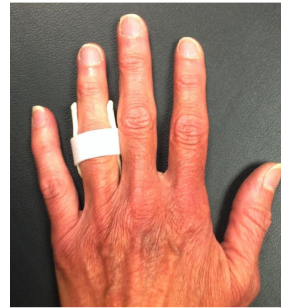Cylinder



Reverse Oval 8



Metal AB



PIP Volar Gutter

Wearing Regime: As above Precautions:

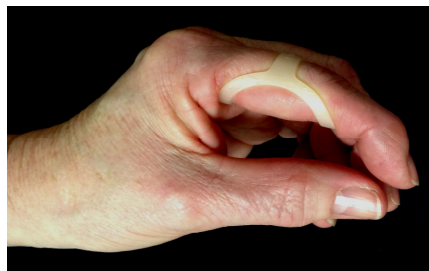- Splint impairs hand function.
- Daily ROM exercise recommended to prevent joint stiffness (see page 4).
- Avoid tight fitting splints, check skin carefully for pressure areas before wearing overnight.

MCP / PIP Limiting Splint

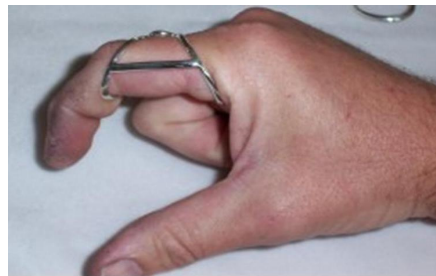Indications: Less restrictive than Palmar Ring splint, allowing improved hand function.

Description: Anti-Swan Neck (ASN) splints are positioned upside down on finger with central bar proximal to the PIP joint. They significantly limit PIP joint flexion and partially limit the MCP joint.

1. Oval 8 ASN: An inexpensive, commercially made option, for day use only.
2. Digisplint Trigger Finger: More expensive custom option, for day use only.



Oval 8 ASN



Digisplint Trigger Finger

Hand Resting Splint

Indications: Used for generalized flexor tenosynovitis, pain at night and problematic finger locking on awakening (4).

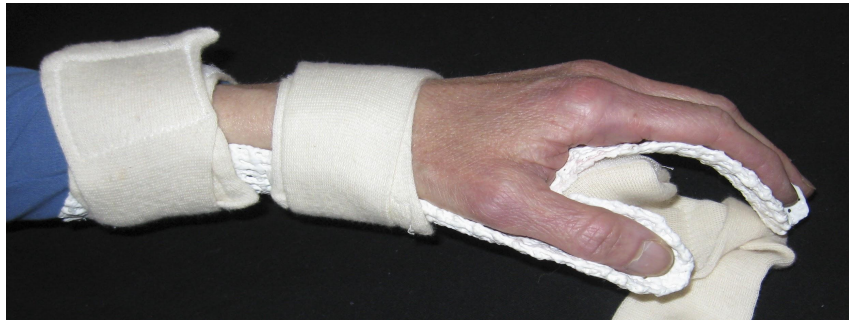Description:

Splint typically supports MCP joints in 15-20° flexion, however it should be reduced to 0-5° to decrease force at A1 pulley. PIPs are positioned in 20° flexion and DIPs in 10° (OT II A-7)

Wearing Regime: Splint worn during rest periods and at night.

Precautions:

- Daily ROM exercise is recommended to prevent joint stiffness (see page 4).
- Avoid tight fitting splints and check skin for pressure areas before wearing overnight.
- Weight of splint may aggravate elbow and shoulder joints.



Hand Resting Splint

Compression

Indications:

Swelling in volar surface of proximal phalange or generalized swelling in palm. Use Digisleeve for single finger swelling and a compression glove for multiple fingers or palmar swelling.

Wearing regime: Can be worn under splint of choice providing it does not compromise splint fit, for day or night use.

Precautions: Re-size or discontinue use if numbness or tingling in the fingers. Discontinue if skin irritation occurs.

Splinting Evidence

- Patel and Bassini reported that full time splinting (MCP 15° flexion, IP free) and extrinsic tendon gliding exercise for 3-9 weeks resolved symptoms in 66% of patients at 1 year follow up vs 84% resolution of symptoms with cortisone injection(s). Diagnoses were not specified (20).
- Evans et al reported 73% of patients achieved good to excellent results with daily splinting (MPJ in 0°, IP free) combined with exercises for 3-6 weeks. No RA included in sample (14).
- Valdes reported that splinting (MCP block or PIP block) decreased pain and Stage of Stenosing Tenosynovitis (SST) reporting an 87% success rate. Mixed diagnoses including RA and OA in sample (16).
- Colbourn et al reported improvement in SST stage, pain, number of triggering events and subjective improvement after 6 weeks with a palmar ring splint (MCP 15°). Almost 50% of subjects had RA (9).

Joint Protection

Flexor tendons are subjected to maximal stress at the A1 pulley as MCP flexion increases. Also stress increases during pinch activities (tip to tip) because the resistance arm is at its longest (5).

Hand Use Guidelines:

- Avoid activities that require tight, prolonged grip, such as holding a steering wheel or a heavy tool. Encourage use of a padded steering wheel cover, padded gloves (e.g. weight lifter's gloves) or modify tools so that the affected area is not stressed.
- Avoid a full or repetitive fist position while symptoms are present (5,18).
- Avoid prolonged, forceful tip to tip pinch with the affected finger (5).
- Avoid power tools that cause vibration or use anti-vibration gloves.
- Avoid pressure in the palm. For example, when holding plastic grocery bags or suitcases use adapted handles, shoulder straps, backpacks or wheels. If the use of a cane is required, it should be padded.

Other Treatments

Corticosteroid Injection

Corticosteroid injection, a non-operative treatment, has a success rate of approximately 50% to 90%, but there is a high rate of recurrence. Injections are less likely to be successful in patients with triggering for more than 6 months, diffuse tenosynovitis and diabetes mellitus.

Lack of improvement after 2 to 3 injections, usually constitutes failure of the treatment.

Injections may be more successful when used in combination with splinting (19,23).

Surgery

Surgery may be indicated when conservative treatment has failed.

References

1. Peter WF, Steultjens MP et al. Interobserver Reliability of the Amsterdam Severity Scale in Stenosing Tenosynovitis (ASSiST). *J Hand Ther* 2009;22(4):355-9.
2. Ryzewicz M, Moriatis Wolf J. Trigger Digits: Principles, Management, and Complications. *J Hand Surg* 2006;31A:135-146.
3. Magee D, Zachazewsk J. et al. Hand, Wrist and Digit Injuries. Chapter 7 In: *Pathology and Intervention in Musculoskeletal Rehabilitation*. Elsevier Health Sciences 2008
4. Makkouk, A, Oetgen, M et al. Trigger finger: etiology, evaluation, and treatment. *Curr Rev Musculoskelet Med* 2008; 1(2): 92–96.
5. Lee MP, Nasser-Sharif S et al. Surgeon's and therapist's management of tendinopathies in the hand and wrist. Chapter 55 In: *Rehabilitation of the Hand and Upper Extremity*, 6th ed. 2011. Hunter EJ, Callahan AD et al (Eds), Mosby:St. Louis. 931-44.
6. Filippucci E, Gabba A et al. Hand Tendon Involvement in Rheumatoid Arthritis: An Ultrasound Study. *Arthritis and Rheum* 2012; 41:752-760.
7. Silver J. et al . Trigger finger. Chapter 33 In: *Essentials of Physical medicine and Rehabilitation*, 2nd ed. 2008 179-182.
8. Hoppenfeld S. Physical examination of the wrist and hand. Chapter 3 In: *Physical Examination of the Spine and Extremities*.1st ed. 1976. Prentice-Hall. p.86.

9. Colbourn J, Heath N et al. Effectiveness of Splinting for the Treatment of Trigger Finger. *J Hand Ther.* 2008; 21(4):336-43.
10. Salim N, Adbullah S. Outcome of corticosteroid injection versus physiotherapy in the treatment of mild trigger fingers. *J Hand Surg Eur* 2012; 37(1):27-34.
11. Grothe H, Power D. What is the best treatment for trigger finger (stenosing tenosynovitis)? *Evidence-Based Practice* 2013; 16(4):9-10.
12. Hartzell T, Rubinstein R et al. Therapeutic Modalities - an Updated Review for the Hand Surgeon. *J Hand Surg* 2012 Mar; 37A: 597-621.
13. Recommended treatment doses for Low Level Laser Therapy. www.walt.nu April 2010
14. Evans R, Hunter J et al. Conservative Management of the Trigger Finger: A New Approach. *J Hand Ther* 1988 Jan-Mar;1(2):59-68.
15. Kisner C, Colby L. Management of Wrist and Hand Disorders and Surgeries. Chapter 19 In: *Therapeutic Exercise* 6th ed. 2012.
16. Valdes K. A Retrospective Review to Determine the Long-term Efficacy of Orthotic Devices for Trigger Finger. *J Hand Ther* 2012 Jan-Mar; 25:89-96.
17. Akhtar S, Bradley M et al. Management and Referral for trigger finger/thumb. *BMJ* 2005 July 331(7507):30-33.
18. Lindner-Tons S, Ingell K. An Alternative Splint Design for Trigger Finger. *J Hand Ther* 1998 July-Sept; 11(3):206-208.
19. Huisstede B, Hoogvliet P et al. Multidisciplinary Consensus Guideline for Managing Trigger Finger: results from the European HANDGUIDE study. *Physical Therapy* 2014 online doi:10.2522/ptj.20130135
20. Patel M, Bassomo L. Trigger fingers and thumb: When to splint, inject or operate. *J Hand Surg* 1992 January 17A(1):110-113.
21. Tarbhai K, Hannah S et al. Trigger Finger Treatment: A Comparison of 2 Splint Designs. *J Hand Surg* 2012 Feb 37A: 243-249.
22. Hsu J, Michael J et al. Trigger finger (stenosing tenosynovitis) *AAOS Atlas of Orthoses and Assistive Devices* 4th ed.;online:0323039316;Elsevier health sciences;01/01/2008.
23. Lotke P, Abboud j et al. Treatment: trigger finger/Clinical Course. *Lippincott's Primary Care Orthopaedics* 2nd ed.; online: 1451173210; Lippincott Williams & Wilkins; 01/01/2014.
24. Alvarez-Nemegyei J, Canoso J. Evidence-Based Soft Tissue Rheumatology: epicondylitis and hand stenosing tendinopathy. *J Clinical Rheumatology* 2004 Feb10(1):33- 40.

Note: (MPAP) refers to clinical practice consensus of the Physiotherapists and Occupational Therapists at Mary Pack Arthritis Program.